https://karnatakajsurg.com/

Karnataka Journal of Surgery

Case Report

Deep-Seated Simplicity: Unmasking Intramuscular Lipomas

Sunil Krishna M[1], MS (General Surgery), Manasa U[1], MS (General Surgery), Shashank N. K. Achar[1], MS (General Surgery), Narendra Ballal[1], MS (General Surgery), Paraashar Ravindranath Rai[1], MS (General Surgery)

[1]Department of General Surgery, Kasturba Medical College Hospital, Udupi, Karnataka, India.

***Corresponding author:**
Narendra Ballal,
Department of General Surgery,
Kasturba Medical College
Hospital, Udupi, Karnataka,
India.
narendra.ballal@manipal.edu

Received: 20 May 2025
Accepted: 16 September 2025
Published: 18 December 2025

DOI
10.25259/KJS_18_2025

Quick Response Code:

ABSTRACT

Intramuscular lipomas (IMLs) are rare benign soft tissue tumours that account for less than 1% of all lipomas and often present a diagnostic challenge due to their deep location and infiltrative growth pattern. We report a case of a 75-year-old male with a 15-year history of a painless, gradually growing swelling over the posterior aspect of the left shoulder. Clinical examination revealed a soft, mobile, non-tender swelling causing no functional limitation. Ultrasonography and magnetic resonance imaging confirmed an intramuscular lipoma involving the deltoid and triceps muscles. The patient underwent complete surgical excision, and histopathological analysis revealed mature adipocytes with no atypia, consistent with benign lipoma. The postoperative course was uneventful, with no signs of complications or recurrence. This case highlights the importance of considering IMLs in the differential diagnosis of deep soft tissue masses.

Keywords: Infiltrative lipoma, Intramuscular lipoma, Lipoma, Sarcoma, Swelling

INTRODUCTION

A lipoma is a benign mesenchymal tumour formed of mature fat tissue and is the most prevalent soft tissue tumour.[1] Different types of lipomas have been classified based on their topographical location, such as intermuscular, intramuscular, synovial, parosteal, intraosseous, lumbosacral, and thymolipoma.[2] Intramuscular infiltrating lipoma is an uncommon variant among these, first documented by Regan *et al*. in 1946.[3] Later, Greenberg *et al*. expanded on this classification, noting that infiltrating lipomas may be intermuscular or intramuscular, according to the system developed by Moriconi, which had distinguished lipomas according to their location between or within muscle.[4] Further refinement in classification has resulted in the identification of intramuscular lipomas (IMLs) occurring in three histological patterns: infiltrative, well-defined (non-infiltrative), and mixed, with regions of both infiltration and distinct margins.[5] Most IMLs present as encapsulated, round or fusiform masses covered by muscle fibres, but some have a large extramuscular component.[6] Because of their depth and ability to simulate more aggressive lesions, familiarity with IMLs is important. Identification of this entity can direct proper diagnosis and surgical intervention.

This is an open-access article distributed under the terms of the Creative Commons Attribution-Non Commercial-Share Alike 4.0 License, which allows others to remix, transform, and build upon the work non-commercially, as long as the author is credited and the new creations are licensed under the identical terms.
©2026 Published by Scientific Scholar on behalf of Karnataka Journal of Surgery.

CASE REPORT

A 75-year-old man presented to the general surgery outpatient department with complaints of painless swelling over his left shoulder, which he first noticed about 15 years ago. The swelling had progressively increased in size over the years but was otherwise asymptomatic. On inspection, a solitary, soft, mobile, non-tender swelling approximately 9 × 10 cm over the posterior aspect of the left shoulder was observed. General physical and systemic examination was unremarkable. Left shoulder ultrasonography showed a well-defined hypoechoic mass measuring 9.0 18.0 × 4.0 cm (Transverse × Cranio-caudal × Anterior-posterior) in the subcutaneous plane over the posterior part of the proximal arm, without internal vascularity. Magnetic resonance imaging (MRI) of the left shoulder [Figure 1] showed an intramuscular lipoma that was mostly in the deltoid and triceps muscles in the posterior compartment of the proximal arm. A diagnosis of intramuscular lipoma was established. The patient underwent excision of lipoma [Figure 2], and histopathological examination showed sheets of matured adipocytes, interspersed with hypocellular fibrous septa with congested thick-walled blood vessels with no atypia. Features consistent with lipoma. Postoperative recovery was uneventful, with no complications. The patient was discharged in stable condition, with no recurrence on follow-up after 6 months.

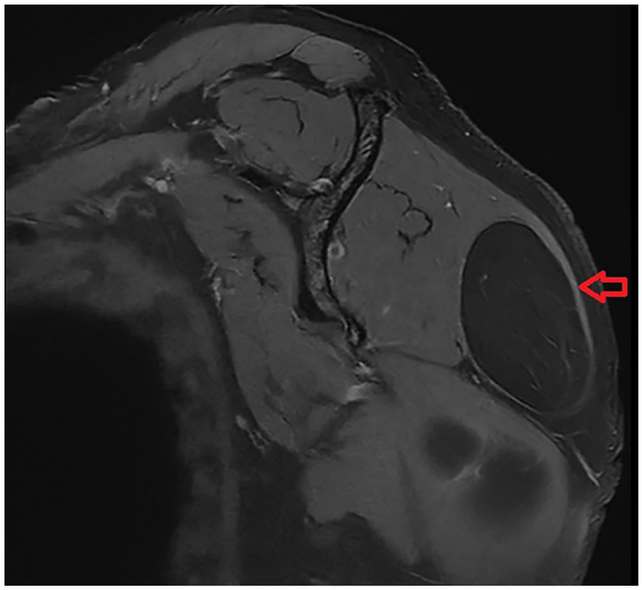

Figure 1: Magnetic resonance imaging of the left shoulder showing intramuscular lipoma (red arrow).

Figure 2: Showing intraoperative picture of intramuscular lipoma.

DISCUSSION

Lipomas are the most common benign mesenchymal tumours with an incidence of about 2.1 per 1,000 persons.[7] IMLs, on the other hand, account for less than 1% of total lipomas and are usually present in people aged 40–70 years. There is no definitive evidence indicating a clear gender predilection. The anatomical distribution of IMLs differs from study to study, but these lesions are more commonly seen in larger muscles of the trunk, head and neck, and extremities. Hand and foot involvement is uncommon. Lipomas over 5 cm in diameter are termed giant lipomas. IMLs are clinically characterised as deep-seated, soft, and non-tender masses. While often asymptomatic, they may become symptomatic as the lipoma increases in size. Pain is usually attributed to compression of adjacent peripheral nerves. Atypical presentations of IMLs have been described, such as those with cutaneous or pedunculated features. For diagnosis, MRI is regarded as the standard of reference based on its high ability to discriminate lipomatous lesions from other soft tissue masses.[8] MRI not only establishes the diagnosis but also assists in the identification of atypical features that may be concerning for malignancy.[9] The treatment of IMLs is based on the size, site, and symptomatology of the tumour. Small asymptomatic lesions can be treated conservatively by being observed. However, surgical excision remains the treatment of choice for symptomatic large lipomas (>5 cm), those causing functional limitation, or when the patient desires removal for cosmetic reasons. Marginal excision is usually adequate, although wide excision with clear margins should be done in those with atypical imaging features or suspected malignancy to reduce the chances of recurrence. Recurrence is a major issue in the management of IMLs, with rates ranging from 50% to 80%, primarily attributed to their infiltrative nature. However, recurrence can be significantly curtailed with wide surgical removal. For instance, a Korean study illustrated a rate of recurrence of 11.1% with marginal excision, as opposed to 0% with wide excision.[10]

CONCLUSION

IMLs are rare benign soft tissue tumours that may remain asymptomatic for years but can present with progressive swelling, discomfort, or functional impairment depending on their size and location. Magnetic resonance imaging serves as an invaluable tool in assessing lesion characteristics and planning management, while histopathological examination is essential for definitive diagnosis. Given the potential for recurrence due to the tumour's infiltrative nature, follow-up is recommended to ensure optimal patient outcomes.

Author contributions: SKM, MU, SNKA, NB, PRR: Concepts, literature search, manuscript preparation, editing and review.

Ethical approval: Institutional Review Board approval is not required.
Declaration of patient consent: The authors certify that they have obtained all appropriate patient consent.
Financial support and sponsorship: Nil.
Conflicts of interest: There are no conflicts of interest.
Use of artificial intelligence (AI)-assisted technology for manuscript preparation: The authors confirm that there was no use of artificial intelligence (AI)-assisted technology for assisting in the writing or editing of the manuscript and no images were manipulated using AI.

REFERENCES

1. Murphey MD, Carroll JF, Flemming DJ, Pope TL, Gannon FH, Kransdorf MJ. From the Archives of the AFIP: Benign Musculoskeletal Lipomatous Lesions. Radiographics 2004;24:1433–66.
2. Mai KT, Yazdi HM, Collins JP. Vascular Myxolipoma ("Angiomyxolipoma") of the Spermatic Cord. Am J Surg Pathol 1996;20:1145–8.
3. Regan, JM, Bickel WH, Broders AC. Infiltrating Lipomas of the Extremities. Surg Gynecol Obstet 1946;54:87.
4. Greenberg SD, Isensee C, Gonzalez-Angulo A, Wallace SA. Infiltrating Lipomas of the Thigh. Am J Clin Pathol 1963;39:66–72.
5. Chernev I. Intramuscular Lipoma: Infiltrating vs. Well-Circumscribed Variant. Pan Afr Med J 2014;17:170.
6. Fletcher CD, Martin-Bates E. Intramuscular and Intermuscular Lipoma: Neglected Diagnoses. Histopathology 1988;12:275–87.
7. Silistreli OK, Durmuş EU, Ulusal BG, Oztan Y, Görgü M. What Should Be the Treatment Modality in Giant Cutaneous Lipomas? Review of the Literature And Report of 4 Cases. Br J Plast Surg. 2005;58:394–8.
8. Rispoli L, Singh JR, Piesco J. Unusual Location of Intramuscular Lipoma Presenting as an Extensor Tendon Tear: A Diagnostic Dilemma. Am J Phys Med Rehabil 2017;96:e162–3.
9. Byeon JY, Hwang YS, Lee JH, Choi HJ. Recurrent Intramuscular Lipoma at Extensor Pollicis Brevis: A Case Report. World J Clin Cases 2023;11:684–91.
10. Han HH, Choi JY, Seo BF, Moon SH, Oh DY, Ahn ST, *et al*. Treatment for Intramuscular Lipoma Frequently Confused with Sarcoma: A 6-Year Restrospective Study and Literature Review. Biomed Res Int 2014;2014:867689.

How to cite this article: Sunil Krishna M, Manasa U, Achar SNK, Ballal N, Rai PR. Deep-Seated Simplicity: Unmasking Intramuscular Lipomas. Karnataka J Surg. 2026;3:32–34. doi: 10.25259/KJS_18_2025