



Case Report

Strangulation Induced Penile Gangrene in a Mentally Challenged Person

H. M. Abhijith¹, MBBS, MS (General Surgery)^{ID}, M. M. Hussain², MBBS, MS, MCh, Urology^{ID}, Mohd Shafuddin¹, MBBS, MS (General Surgery)
Vitthal Prasad Haribhat¹, MBBS, JR-3

Departments of ¹General Surgery, and ²Urology, Gulbarga Institute of Medical Science, Gulbarga, Karnataka, India

*Corresponding author:

H. M. Abhijith,
Department of General Surgery,
Gulbarga Institute of Medical
Science, Gulbarga, Karnataka,
India

abhijithhiremath@gmail.com

Received: 22 September 2024

Accepted: 21 January 2025

Published: 14 February 2025

DOI

10.25259/KJS_16_2024

Quick Response Code:



ABSTRACT

Penile gangrene is a rare entity, seen most commonly in patients using rings at the root of the penis for erection and rarely with ischaemia from various causes like self-harm, accidents, or assaults. Penoscrotal constriction devices, utilised for sexual enhancement, employ diverse materials. Conversely, penile strangulation, a rare urological emergency, requires swift intervention to prevent severe complications like necrosis. Treatment often demands an early intervention. A mentally challenged 25-year-old boy presented with suspected penile gangrene. Examination revealed multiple rubber bands constricting the base of the penis, causing strangulation. Urgently, the bands were removed in the emergency room (ER). Imaging showed a complete lack of blood flow with gangrenous changes, resulting in urethrocutaneous fistula total penectomy with perineal urethrostomy done. The earliest publication on this condition noted rubber bands as the most common strangulation agents in paediatric cases, with a mean age of 7.5 years. Chronic strangulated partial penile amputation cases are rare, possibly making this report the first. Previously introduced a five-point grading scale for penile strangulation injuries. Penile amputation constitutes a rare urological emergency, necessitating prompt surgical intervention for restoration for cosmetic and functional recovery and erectile capability. Reconstruction efforts should be aimed at every individual case. For those who report late to the ER, it may become difficult to preserve the anatomical and physiological function of the penis. Additionally, psychological support and counselling for affected individuals are crucial aspects of clinical care.

Keywords: Foreign body, Penectomy, Penile strangulation, Penis, Urethroplasty, Urology

INTRODUCTION

Penile strangulation is an uncommon surgical emergency that arises from self-injury, mistakes involving circumcision, attacks, or interactions with animals. Various materials are utilised in penoscrotal constriction devices, which are used for autoeroticism or prolonged erections. On the other hand, penile strangulation is an uncommon urological emergency that requires immediate attention to avoid permanent damage. The main objective is the timely removal of foreign objects, which is frequently difficult and calls for creativity and a multidisciplinary approach.^[1]

A rare urological emergency called penile strangling is caused by the trapping of a foreign item, which can limit blood flow and possibly cause necrosis. In order to avoid serious consequences such as sepsis or gangrene, prompt care is essential.^[2] Age-group-specific incidents range from hair tourniquets in paediatric instances to self-applied objects, such as metallic items or plastic bottles, in adult cases, which are frequently connected to wishes for sexual enhancement or curiosity.^[3] Most of the time, imaging is not necessary while performing penile amputation

as a surgical emergency.^[4] The goal of treatment is timely removal, which is complicated and calls for a multidisciplinary approach.^[5,6] This paper provides an overview of our urethral reconstruction experience following a singular instance of penile gangrene brought on by self-strangulation.

CASE REPORT

A mentally challenged 25-year-old boy was admitted to our hospital with a possible case of penile gangrene. Several rubber bands with adhesions in the base of the penis were discovered during an inspection of the external genitalia, which resulted in the constriction ring and strangulation of the penis [Figure 1]. The penis was chilly, sensitive, and oedematous in the area distal to the band. The area around the constriction band was flowing with urine [Figure 2]. In the emergency department, the rubber bands were removed right away. A neglected youngster had a persistent case of strangulated penile gangrene, and the boy was unable to cooperate with his parents. No blood flow with gangrenous alterations was seen in the entire penis on imaging. He underwent a total penectomy, bilateral orchidectomy, and urethroplasty. Postoperatively, we kept him on a silicone catheter for 4 weeks, and on follow-up, no complications were noted.

DISCUSSION

The most popular strangulation in the paediatric population, with a mean age of 7.5 years, was listed in the first publication on this ailment. Penile amputation is an uncommon and difficult injury; it is treated as an emergency, much like other severe penile injuries such as penile fractures, penetrating penile injuries, and penile soft tissue injuries.^[7] Penile strangulation or incarceration is frequently caused by applying constricting objects, such as iron rings or rubber bands, to the penis. This can result in severe swelling, skin ulcerations, and necrosis.^[6] The first course of treatment usually is removing the object and then fixing any damage.

Based on their treatment of eight patients, Bhat *et al.* developed a five-point grading system for penile strangulation injuries.^[5] The distal penis could have oedema ranging from grade 1 (no urethral damage or skin ulceration) to grade 5 (gangrene, necrosis, or total amputation of the distal penis).^[5] The limited sample size may have contributed to the lack of widespread adoption of this grading system.

Placements of strangulation agents made accidentally or out of curiosity were restricted to the paediatric population. The elderly group was the only demographic to receive strangulation agents for incontinence. In this instance, a urethral tear and non-viable corpora spongiosum muscles

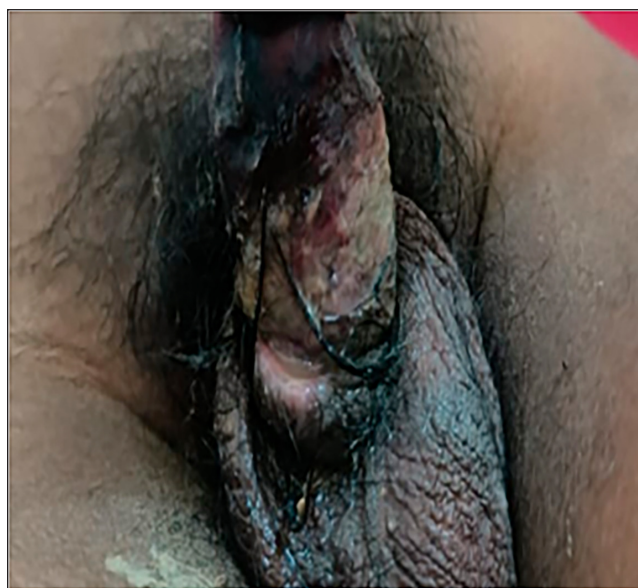

Figure 1: Rubber band piece at the base of the penis.

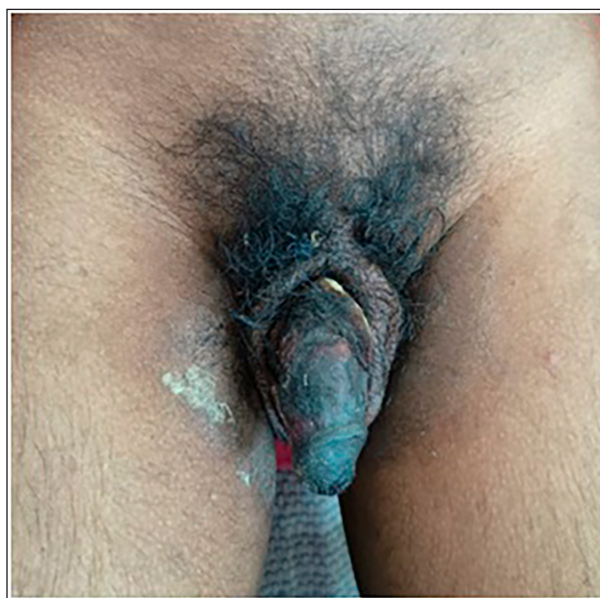


Figure 2: Gangrenous penis with constriction band around it.

necessitated a penectomy along with bilateral orchidectomy and urethroplasty.^[8]

Author contributions: HMA: Writing the paper and operating surgeon; MMH: Writing paper, operating surgeon, writing paper, and correction; MS: Study concept and writing the paper, correction of the paper; VPH: Writing the paper, operating surgeon.

Ethical approval: Institutional Review Board approval is not required.

Declaration of patient consent: The authors certify that they have obtained all appropriate patient consent.

Financial support and sponsorship: Nil.

Conflicts of interest: There are no conflicts of interest.

Use of artificial intelligence (AI)-assisted technology for manuscript preparation: The authors confirm that there was no use of artificial intelligence (AI)-assisted technology for assisting in the writing or editing of the manuscript and no images were manipulated using AI.

REFERENCES

1. Usuda D, Kaminishi N, Kato M, Sugawara Y, Shimizu R, Inami T, et al. Penile and Scrotal Strangulation by Stainless Steel Rings in an Human Immunodeficiency Virus Positive Man: A Case Report. *World J Clin Cases* 2023;11:5811–6.
2. Ivanovski B, Malhi GS. The Psychological and Neurophysiological Concomitants of Mindfulness Forms of Meditation. *Acta Neuropsychiatr* 2007;19:76–91.
3. Perabo FG, Steiner G, Albers P, Müller SC. Treatment of Penile Strangulation Caused by Constricting Devices. *Urology* 2002; 59:137.
4. Maimaitiming ABLT, Mulati YLSD, Apizi ART, Li XD. Self-Strangulation Induced Penile Partial Amputation: A Case Report. *World J Clin Cases* 2023;11:5373–81.
5. Bhat AL, Kumar A, Mathur SC, Gangwal KC. Penile Strangulation. *Br J Urol* 1991;68:618–21.
6. Campbell KJ, Kwenda EP, Bozorgmehri S, Terry RS, Yeung LL. Penile Strangulation: Analysis of Postextrication Follow-Up, Sequelae, and a Review of Literature. *Am J Men's Health* 2024;18:15579883231223366.
7. Patial T, Sharma G, Raina P. Traumatic Penile Amputation: A Case Report. *BMC Urol* 2017;17:93.
8. Agha RA, Franchi T, Sohrabi C, Mathew G, Kerwan A, Thoma A, et al. The SCARE 2020 Guideline: Updating Consensus Surgical Case Report (SCARE) Guidelines. *Int J Surg* 2020;84: 226–30.

How to cite this article: Abhijith HM, Hussain MM, Shafuiddin M, Haribhat VP. Strangulation Induced Penile Gangrene in a Mentally Challenged Person. *Karnataka J Surg.* 2025;2:37–39. doi: 10.25259/KJS_16_2024