

## Case Report

# Management of Postprostatectomy Gossypiboma and Organised Clot Retention

Abdullahi Khalid<sup>1</sup>, MBBS, FWACS , Ibrahim Umar Abubakar<sup>1</sup>, MBBS, FWACS, Nasiru Abubakar<sup>2</sup>, MBBS, FMCPath, Abubakar Musa<sup>3</sup>, MBBS, FMCR, Abubakar Sadiq Muhammad<sup>1</sup>, MBBS, FMCS, FWACS , Yusuf Saidu Umar<sup>4</sup>, MBBS

<sup>1</sup>Department of Surgery, Institute of Urology and Nephrology, Usmanu Danfodiyo University and Teaching Hospital, Sokoto, Departments of <sup>2</sup>Pathology, <sup>3</sup>Radiology, <sup>4</sup>Surgery, Federal Medical Centre, Gusau, Nigeria

### \*Corresponding author:

Abdullahi Khalid,  
Department of Surgery,  
Institute of Urology and  
Nephrology, Usmanu  
Danfodiyo University and  
Teaching Hospital, Sokoto,  
Nigeria

[kalabduka@gmail.com](mailto:kalabduka@gmail.com)

Received: 15 December 2024

Accepted: 14 January 2025

Published: 14 February 2025

### DOI

10.25259/KJS\_26\_2024

### Quick Response Code:



## ABSTRACT

The treatment of patients with prostatic diseases is dependent upon the type and nature of the disease. The open prostatectomy for benign prostatic hyperplasia (BPH) is still relatively common in low- and middle-income countries despite one of its dreadful haemorrhagic complications and the attendant morbidity and mortality. This is a report of a 70-year-old retired farmer who was referred from a private health facility after open transvesical prostatectomy for an initial diagnosis thought to be BPH. He developed haemorrhagic complications with retained organised blood clot and gossypiboma warranting resuscitation, re-exploration, and removal with subsequent histological confirmation of prostate cancer. The patient, however, succumbed to the second haemorrhagic episode. Haemorrhage is a dreaded complication of open transvesical prostatectomy and a key cause of morbidity and mortality. Proper patient evaluation and selection for open prostatectomy can avert possible disaster.

**Keywords:** Clot retention, Gossypiboma, Prostatectomy, Prostate cancer

## INTRODUCTION

The treatment of patients with prostatic diseases is dependent upon the type and nature of the disease. While the treatment of prostate cancer is largely radical in approach, especially when seen at early stages, the non-radical approach is used for benign prostatic diseases, especially benign prostatic hyperplasia (BPH).<sup>[1]</sup> The non-radical treatment for BPH is achievable by means of either medications or surgery, depending on the indications.<sup>[2]</sup> The surgical options for BPH include open surgical techniques, endoscopic, laparoscopic, and robotic approaches. Open prostatectomy is still relatively common in low- and middle-income countries despite its associated complications, such as haemorrhage, which could occur primarily as reactionary or secondarily resulting in clot retention.<sup>[3,4]</sup> Bleeding prostate cancer is also a familiar aetiology that can lead to clot retention.<sup>[5,6]</sup> Beyond open prostatectomy, catastrophic bleeding complications from other conditions and even unrecognised aetiology, including amyloidosis, have been observed.<sup>[7,8]</sup> There have been several reports of bleeding or haemorrhage as a complication seen in patients with unusual or uncommon histological types of prostate cancer, especially the neuroendocrine type, due to their aggressive nature.<sup>[9-11]</sup> This histological type is observed to be relatively rare and not associated with prostate-specific antigen (PSA) rise.<sup>[12]</sup> Therefore, overreliance on the use of PSA in the evaluation of the rare cohort of patients suspected of

This is an open-access article distributed under the terms of the Creative Commons Attribution-Non Commercial-Share Alike 4.0 License, which allows others to remix, transform, and build upon the work non-commercially, as long as the author is credited and the new creations are licensed under the identical terms.

©2025 Published by Scientific Scholar on behalf of Karnataka Journal of Surgery.

neuroendocrine prostate cancer may be misleading with dire consequences.<sup>[10]</sup> Hence, an unsuspecting attending physician may consider BPH with high priority in the list of his differential diagnoses of middle-age or elderly man presenting with lower urinary tract symptoms and normal serum PSA.

Surgical complications are well-documented findings in the surgical literature, and a specialist trainee is often equipped with them and the ways to avoid or minimise them. At times adequate knowledge of patients' pathology can help the surgeon to better anticipate at-risk patients in order to avert possible morbidity and mortality that may be the outcome. Therefore, a surgeon's training, experience, and skills are put to task during clinical evaluation, choice, and interpretation of investigative findings, as well as guide the choice and decisions at the preoperative and postoperative phases of patient care. Postprostatectomy gossypiboma is a rare and possible complication of open prostatectomy for both BPH or misdiagnosed prostate cancer-associated haemorrhagic challenges.<sup>[13,14]</sup> This is common in the face of a dramatic severe intraoperative haemorrhage where the surgical team loses count of the surgical armamentarium, such as gauze. Gossypiboma should be a serious cause for worry to the surgical team because of possible medicolegal sanctions.<sup>[15]</sup> Furthermore, and for similar reasons and concerns, it has been noted that cases of gossypiboma are grossly underreported in the literature.<sup>[16]</sup> This is largely wrong because the enormous lessons that can be derived by the health care team from such scenarios without such experience are often lost. This trend should be discouraged as much as possible to prevent or minimise repeat future occurrence.<sup>[15]</sup> Our objective is to report our experience in the management of a case of postprostatectomy gossypiboma and retained organised clot.

## CASE REPORT

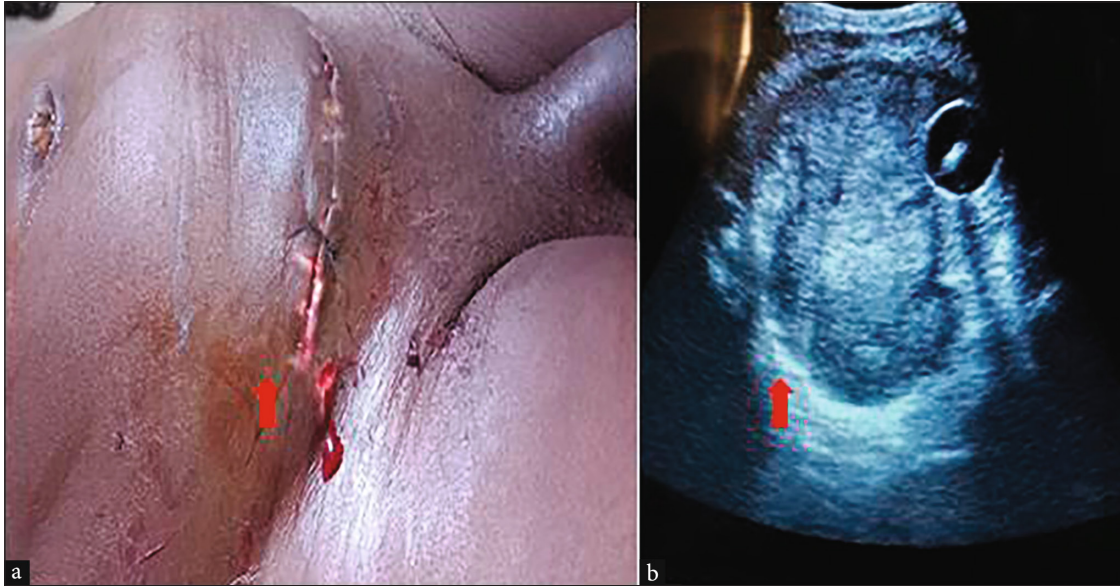
This is a 70-year-old retired farmer who was referred from a private health facility and admitted into the emergency department of our facility two weeks after an open transvesical prostatectomy. He presented with the history of progressive suprapubic swelling and pain, fever, and haematuria within two weeks after prostatectomy. There was an associated history of dizziness and body weakness but no history of syncope or loss of consciousness. He had no history to suggest bleeding or coagulation disorder. There was no history of use of antiplatelets or anticoagulants. There was a history of longstanding low backache, but other history of prostate cancer, including family history and history of metastasis, was unremarkable except for the recent development of bilateral lower limb swelling post prostatectomy. The initial resuscitation at the referring

health facility included passage of a 3-way silicon urethral catheter and normal saline bladder irrigation, antibiotics, analgesics, and intravenous normal saline infusion, but to no avail, necessitating the referral. He had four pints of blood transfusions perioperatively at the same facility.

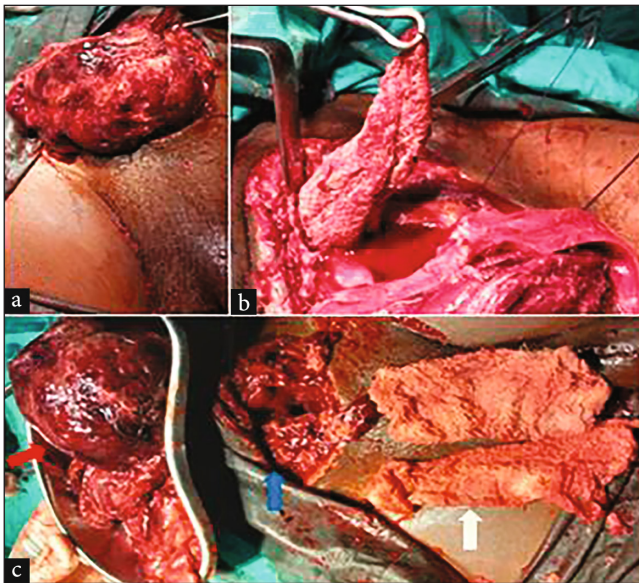
On physical examination, he was an elderly man, acutely ill-looking, in painful distress, pale and dehydrated. His temperature, respiratory rate (RR), pulse rate (PR) and blood pressure (BP) were 38.0 C, 20 cycles/minute, 108 bpm, and 100/60 mmHg, respectively. The chest examination was not remarkable. The suprapubic region was distended and tender with egress of bloody effluents from the transverse infraumbilical suprapubic operative wound [Figure 1a], and an in situ 3-way, 24 Fr silicone urethral catheter connected to an empty urine bag. The prostate on digital rectal examination was indurated and suspicious of prostate cancer (probably due to a recent prostate surgery). The anal sphincter and anal reflexes were intact. The sensations and power in the limbs were satisfactory.

The PSA was within normal range (2.20 ng/ml). The other laboratory investigations showed leucocytosis and packed cell volume of 26%. The serum urea, creatinine, and electrolyte parameters were within normal limits. The urine culture yielded growth of *Echerichia coli* sensitive to ceftriaxone, among others. The transabdominal ultrasound scan showed a huge mixed echogenic mass filling the entire bladder cavity and displacing the indwelling urethral catheter balloon superolaterally, consistent with a huge retained bladder clot [Figure 1b].

He was preoperatively diagnosed to have postprostatectomy clot retention. He was resuscitated with intravenous normal saline and transfused two units of blood, antibiotics, and analgesics preoperatively and counselled for emergency bladder exploration. The intraoperative findings included a huge retained organised blood clot weighing 550 g and gossypiboma (two pieces of surgical gauze pack) filling the entire bladder cavity [Figures 2a-c]. The prostatic fossa was filled with necrotic and easily friable tissues suspicious of prostate cancer with multiple areas of diffuse bleeding. The bladder clot was completely evacuated with the gauze packs, and the prostatic fossa tissues were taken for histological examination. The Harris stitches were reapplied in addition to other haemostatic stitches. The bleeding from the prostatic bed reduced significantly, but a series of gauze pieces were tied together and used to pack the prostatic fossa around the insitu urethral catheter, and part of it was brought out through the bladder and the abdominal wound for easy removal postoperative. A suprapubic cystostomy catheter was left in situ for normal saline bladder irrigation postoperative. An additional two pints of blood were transfused intraoperatively. The diagnosis of



**Figure 1:** Clinical and radiological findings at presentation: (a) Distended suprapubic region by bladder filled with retained gossypiboma and organized blood clot (red arrow), (b) Transabdominal ultrasound scan showing bladder filled with retained and organized blood clot and echogenic areas probably gossypiboma, and an insitu catheter balloon (red arrow).



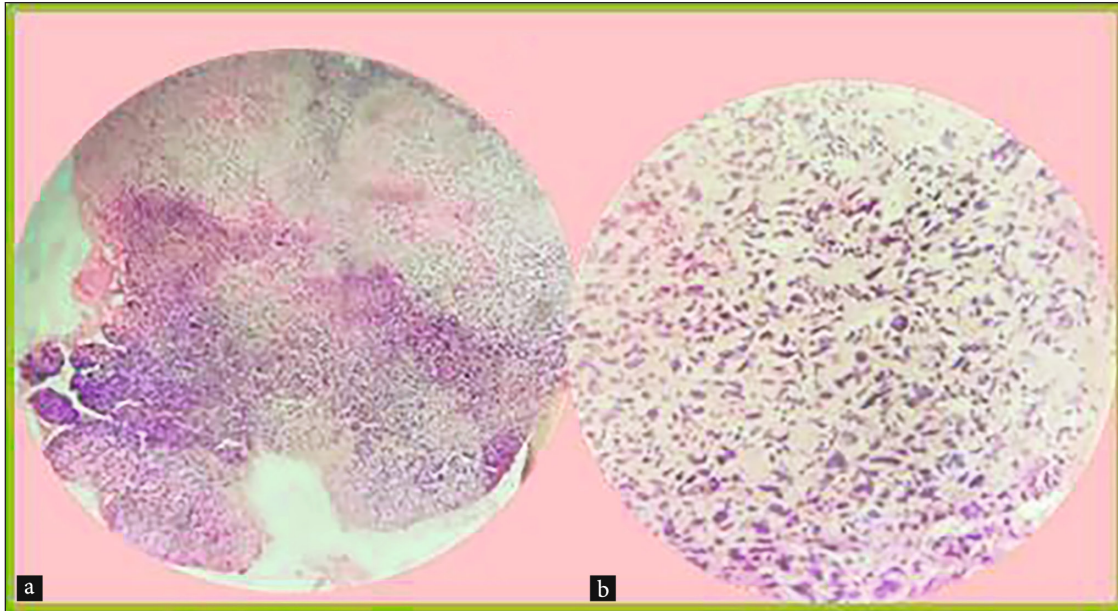
**Figure 2:** Intraoperative findings. (a) Organized retained clot being mobilized out of the bladder, (b) Forgotten or retained surgical gauze being removed out of the bladder. (c) Evacuated organized retained clot, two retained surgical gauze pieces and bladder cavity (red, white and, blue arrows).

postprostatectomy gossypiboma with retained organised blood clot was confirmed intraoperatively. Postoperatively, the patient was generally stable; the prostatic fossa pack was removed on the 5<sup>th</sup> postoperative day. While awaiting the histology report, he was counselled and commenced on oral antiandrogen (bicalutamide 150 mg daily).

On the 12<sup>th</sup> postoperative day, the histology showed fragments of tissues comprising a tumour that is disposed in a diffuse single-cell pattern with the composing cells showing marked pleomorphism and having round to ovoid to elongated hyperchromatic to vesicular nuclei with prominent nucleoli and a variable amount of cytoplasm. The haemorrhage and necrosis were seen and confirmed a poorly differentiated prostate carcinoma [Figures 3a,b]. However, suggested immunohistochemistry for proper characterisation. On the same day, the patient, however, developed another episode of significant haematuria, associated with suprapubic swelling and pain with transabdominal ultrasound scan confirmation of bladder clot. This time, it was quite dramatic, with haemodynamic instability and eventually hypovolaemic shock. The attempt at resuscitation and plan to return him to the theatre immediately was abortive as he passed on while on resuscitation.

## DISCUSSION

Surgical interventions, whether minor or major, have attendant sequelae. Out of the known complications of open prostatectomy, perioperative haemorrhage is dreadful to the surgeon.<sup>[3,4,17]</sup> Because of the significant threat it poses to the patient during and after the surgery, including but not limited to hypovolaemic shock cardiac arrest, among others. At times, it can be the background reason for the morbidity and mortality suffered by these patients. This haemorrhage can be so dramatic and severe, presenting a significant challenge to the entire surgical team, whose main task is to



**Figure 3:** Histologic findings of the patient showing a poorly differentiated carcinoma (a) Photomicrograph with haematoxylin and eosin (H & E) stain at x 100 magnification and (b) H & E stain at x 400 magnification.

secure haemostasis. At the same time, ensuring that adequate, effective circulatory blood volume and end-organ tissue perfusion are maintained by a dedicated multidisciplinary team. The principle of management of haemorrhage includes resuscitation, identification of the cause, and treatment of the identified aetiology.<sup>[18]</sup>

The index patient had resuscitation with crystalloids and blood followed by bladder exploration with the removal of the retained blood clot and gossypiboma, haemostasis with stitches, and prostatic fossa gauze packing. The treatment of prostate cancer could not be initiated immediately due to the non-availability of histological reports of the initial prostatic tissues from the referral facility. The subsequent postoperative confirmation of prostate cancer was delayed. Otherwise, hormonal treatment for prostate cancer through medical or surgical castration may be helpful in treating the underlying cause of haemorrhage in the patient. The additional challenge was the inability to do immunohistochemistry for proper prostate cancer characterisation due to out-of-pocket payment, which was obviously exhaustive to the patient and caregivers. Moreover, this case had clinical and laboratory findings which were suggestive or suspicious of a neuroendocrine prostate cancer with a known propensity to cause haemorrhage as reported in some studies. Unfortunately, he had a second episode of haemorrhage with recurrence of bladder clot and haemodynamic instability, which led to the patient's demise. Therefore, there is a need for the government to introduce a system of national health insurance that can cater to more citizens, especially the ones in the informal sector.

Furthermore, the index case management and outcomes also underscore the significance of proper training, early recognition, and diagnosis or referral by non-specialist colleagues to tertiary health facilities of patients with some subtle suspicious findings of prostate cancer. These were present in this patient and included the patient's age and suspicious digital rectal examination, which were enough reasons for prostate biopsy before the initial surgery at the private health facility. The nonavailability of histological reports from the private health facility further compounded or delayed the diagnosis of prostate cancer, which became apparent after bladder exploration and removal of the retained blood clot and gossypiboma.

The lesson from this case management indicates that all hands must be on deck to avert future disasters. Hence, the government and particularly the national medical and dental councils regulating the medical profession may need to come up with firmer policies and regulations which restrict the performance of some technical urological surgeries by the nonurologist at the private and secondary health facilities nationwide. They can also give tougher sanctions to erring officers and facilities for noncompliance in order to deter others.

## CONCLUSION

Haemorrhage is a dreaded complication of open transvesical prostatectomy and a key cause of morbidity and mortality in addition to the development of postprostatectomy gossypiboma and retained organised blood clot. Treatment of postprostatectomy gossypiboma and clot retention required

prompt resuscitation and emergency bladder exploration with the evacuation of the retained blood clot and gossypiboma to guarantee patient survival and treatment of any identified aetiology. Hence, proper patient evaluation and selection for open prostatectomy can avert possible disaster.

**Author contributions:** AK and IUA: Conceptualization; AK, IUA, NA, AM and YSU: Data curation; AK, IUA, NA, ASM, AM and YSU: Writing of the initial draft; AK, IUA, and NA: Methodology; AK, NA, ASM,: Visualization and supervision; AK, IUA, NA, AM and YSU: Resources, software work and validation; AK, IUA, NA, AM, ASM and YSU: Reviewing and editing.

**Acknowledgement:** We wish to appreciate our hospital staffs who contributed to his care while on admission at our facility.

**Ethical approval:** The research/study approved by the Institutional Review Board at Research and Ethics Committee, Federal Medical Centre, Gusau, Zamfara state, Nigeria, number FMC/2021/985/008/NHREC/TR/19/03/2016, dated 20th October 2024.

**Declaration of patient consent:** The authors certify that they have obtained all appropriate patient consent.

**Financial support and sponsorship:** Nil.

**Conflicts of interest:** There are no conflicts of interest.

**Use of artificial intelligence (AI)-assisted technology for manuscript preparation:** The authors confirm that there was no use of artificial intelligence (AI)-assisted technology for assisting in the writing or editing of the manuscript and no images were manipulated using AI.

## REFERENCES

- Keyes M, Crook J, Morton G, Vigneault E, Usmani N, Morris WJ. Treatment Options for Localized Prostate Cancer. *Can Fam Physician* 2013;59:1269–74.
- Lokeshwar SD, Harper BT, Webb E, Jordan A, Dykes TA, Neal Jr DE, et al. Epidemiology and Treatment Modalities for the Management of Benign Prostatic Hyperplasia. *Transl Androl Urol* 2019;8:529.
- Salako AA, Badmus TA, Owojuyigbe AM, David RA, Ndegbu CU, Onyeze CI. Open Prostatectomy in the Management of Benign Prostate Hyperplasia in a Developing Economy. *Open J Urol* 2016;6:179–89.
- Ottaiano N, Shelton T, Sanekommu G, Benson CR. Surgical Complications in the Management of Benign Prostatic Hyperplasia Treatment. *Curr Urol Rep* 2022;23:83–92.
- Ramyil VM, Dakum NK, Liman HU, Udeh EI. The Management of Prostatic Haematuria. *Niger J Med* 2008;17:439–42.
- Kafor MB, Nnadi GI, Onuigbo WI. Haematuria in Benign, Prostatic Hyperplasia and Prostatic Carcinoma. *Prostate* 2019;67:1:29.
- Missen GA, Tribe CR. Catastrophic Haemorrhage From the Bladder Due to Unrecognised Secondary Amyloidosis. *Br J Urol* 1970;42:43–9.
- Zehnder JL. Drugs Used in Disorders of Coagulation. *Basic Clin Pharmacol* 2018;11:587–99.
- Mazzucchelli R, Lopez-Beltran A, Cheng L, Scarpelli M, Kirkali Z, Montironi R. Rare and Unusual Histological Variants of Prostatic Carcinoma: Clinical Significance. *BJU Int* 2008;102:1369–74.
- Deng L, Li C, He Q, Huang C, Chen Q, Zhang S, et al. Superselective Prostate Artery Embolization for Treatment of Severe Haematuria Secondary to Rapid Progression of Treatment-Induced Neuroendocrine Prostate Cancer: A Case Report. *Onco Targets Ther* 2022;20:67–75.
- Aggarwal R, Zhang T, Small EJ, Armstrong AJ. Neuroendocrine Prostate Cancer: Subtypes, Biology, and Clinical Outcomes. *J Natl Compr Cancer Net* 2014;12:719–26.
- Kránitz N, Szepesváry Z, Kocsis K, Kullmann T. Neuroendocrine Cancer of the Prostate. *Pathol Oncol Res* 2020;26:1447–50.
- Shaikh AR, Shaikh NA, Abbasi A, Soomro MI, Memon AA. Foreign Bodies in the Urinary Bladder. *RMJ* 2010;35:194–7.
- Umunna JL. Gossypiboma and Its Implications. *J West Afr Coll Surg* 2012;2:95.
- Iype GR, Samarasam I, Senthilnathan K, Yacob M, Abraham VP. Intra-Abdominal Gossypibomas: Clinical Manifestations, Risk Factors and Prevention. *Indian J Surg* 2021;83:885–91.
- Irabor DO. Under-Reporting of Gossypiboma in a Third-World Country. A Sociocultural View. *Health* 2012;4:56–9.
- Chute AL. Some of the Complications of Prostatectomy. *J Urol* 1929;21:711–28.
- Costa-Pinto R, Borgstedt L, Lakbar I. Principles and Management of Haemorrhagic Shock. In *Best 2022 Clinical Cases in Intensive Care Medicine: From the ESICM NEXT Committee Clinical Case Contest 2023*;487–94.

**How to cite this article:** Khalid A, Abubakar IU, Abubakar N, Musa A, Muhammad AS, Umar YS. Management of Postprostatectomy Gossypiboma and Organised Clot Retention. *Karnataka J Surg.* 2025;2:32–36. doi: 10.25259/KJS\_26\_2024